

ANSWER CASE HISTORY I

Normal mental status and cranial nerves with diffuse weakness of limb and axial muscles, decreased reflexes and muscle tone and normal sensation suggest a peripheral lesion within a motor unit (anterior horn cells, motor nerve, neuromuscular junction or muscle). If the boy's weakness were caused by a lateral corticospinal tract lesion you would expect increased muscle tone (spasticity), hyperactive tendon reflexes and extensor plantar reflexes (Babinski sign).

Electrodiagnostic evaluation would help to localize the defect more precisely within the motor unit.

Nerve conduction studies were normal. This points away from the possibility of a demyelinating process. There was evidence of small amplitude motor unit potentials (MUPs) in all muscles tested. These "myopathic" changes are very suggestive of a condition affecting the muscle (myopathy).

To confirm this, you should check the creatine kinase (CK) level in serum (nonspecific marker of muscle disease). Indeed, the CK was very high - 15,000 U/l (normal range is 0 - 250) confirming your suspicion from the clinical exam and the EMG that this boy suffers from severe muscle disease. An experienced clinician, given the above presented scenario, might have checked the CK even before the electrodiagnostic test. A very high creatine kinase value indicates severe muscle fiber breakdown (necrosis).

At this point you should consider different, possible etiologies of a myopathy (muscle disease) (is it a primary degeneration of muscle, metabolic/toxic abnormality, inflammation?).

Examination of a muscle specimen would be helpful.

Muscle biopsy showed clusters of necrotic and regenerating muscle fibers and severe proliferation of fibrous and fatty connective tissue. These findings unequivocally point to the muscle as a cause of weakness.

To "pinpoint" the diagnosis you may order some special stains. The clinical presentation, very high CK and the findings from the muscle biopsy, are very suggestive of so called dystrophinopathy (severe muscle disease also known as Duchenne muscular dystrophy).

Special stains to look for expression of a potentially deficient protein (dystrophin) are now available.

Immunocytochemical staining against the dystrophin molecule showed no reactivity.

The DNA analysis showed a deletion within the dystrophin gene (Xp21 locus).

With your systematic and thorough work up you not only localized the defect causing the weakness (muscle) but also determined which specific protein (dystrophin) is deficient in the muscle and what events at a molecular level led to its deficient expression (deletion within the gene coding for dystrophin).

SUMMARY

The term **muscular dystrophy** refers to a genetically determined, progressive muscle disease characterized clinically by progressive muscle weakness and atrophy and histopathologically by muscle fiber necrosis, regeneration and replacement of muscle by connective tissue elements. This connective tissue leads to the increase in size of the muscles. Also the remaining fibers hypertrophy.

Duchenne muscular dystrophy is an X-linked recessive condition. The onset of weakness is usually in early childhood, however affected children have marked elevation of creatine kinase already at birth. X-linked recessive inheritance means that boys are affected and girls are usually unaffected or very mildly affected carriers. However in some, unusual circumstances, e.g. in Turner syndrome (XO) or X-autosomal translocation, girls may be affected as well. The disease is caused by mutation within the dystrophin gene which is located in the Xp21 locus. About two-thirds of cases are inherited and one-third of new cases are caused by spontaneous mutations. The dystrophin gene is one of the largest in humans, therefore it is prone to frequent mutations. The dystrophin protein is important for the function of the muscle membrane (sarcolemma). Defects in the muscle membrane lead to muscle fiber necrosis. A milder form of Xp21 muscular dystrophy also caused by mutation within the same dystrophin gene is called Becker dystrophy. These patients have usually a milder course and may be able to ambulate independently until the third or fourth decade of life.

Duchenne muscular dystrophy is a progressive disorder. Most boys lose the ability to walk independently before the age of 12. Ultimately, respiratory muscles are affected which leads to respiratory failure and death usually because of associated respiratory infections before the age of 20. In many patients there is involvement of the heart muscle and a proportion of boys die of cardiac failure or arrhythmias.

In about 60 percent of cases, the diagnosis can be made by a DNA analysis (patients with DNA deletions or duplications). In the remaining 30 to 40 percent (point mutations), diagnosis is made by muscle biopsy and specifically by immunocytochemical stains against the dystrophin molecule. In most instances the phenotype may be predicted from the nature of the mutation. Even large deletions with preservation of the reading frame ("in-frame" mutations) usually lead to a relatively benign phenotype (Becker), whereas mutations causing a shift of the reading frame ("out of frame" mutations) lead to termination of translation and produce a very short, truncated dystrophin protein with the result being a more malignant, Duchenne form of this disease.

Because of the devastating nature of this condition, genetic counseling is of paramount importance. A son of a female carrier has a 50% chance of being affected and a daughter has a 50% chance of becoming a carrier. Prenatal diagnosis is possible. Currently there is no specific treatment for Duchenne muscular dystrophy. There are some hopes that gene transfer technology may bring some progress in the future.

ANSWER CASE HISTORY II

The diffuse weakness with normal muscle tone, reflexes and absence of sensory findings suggest disorder within the motor unit (anterior horn cells, motor nerve, neuromuscular junction or muscle). A lesion in the lateral corticospinal tract would cause increased muscle tone, hyperactive tendon reflexes and extensor plantar reflexes. The fluctuating weakness that increases with activity or exercise and improves with rest is characteristic for a defect in neuromuscular transmission.

To confirm your suspicion and to rule out the possibility of peripheral nerve, muscle or anterior horn cell involvement you should order electrodiagnostic studies and specifically request a repetitive stimulation test. This was done and showed normal conduction velocities and normal needle examination. Repetitive stimulation at 2 Hz showed decremental response indicative of neuromuscular transmission defect.

You may also consider performing a Tensilon (edrophonium) test. This medication inhibits the acetylcholinesterase (i.e. keeps acetylcholine around longer) and after intravenous injection improves, for a short time, the neuromuscular transmission, especially in patients with a postsynaptic defect.

This test was positive, with marked improvement of all symptoms and signs within two minutes after injection of a few milligrams of Tensilon.

There are several toxic conditions (e.g. organophosphate poisoning) or medications that may impair the neuromuscular transmission, however the clinical scenario presented to you is most typical of an immune-mediated condition known as myasthenia gravis (MG). Most patients with this condition have circulating antibodies against the ACh receptors. This test was positive.

MG may be associated with a malignant tumor called thymoma, therefore chest X-Ray or preferably chest CT should be ordered. In this patient there was no evidence of a tumor but only mild hyperplasia (increase in cells) of the thymus.

You may also order blood work to screen for some other conditions associated with MG (e.g. thyroiditis) - this will be discussed with you.

MYASTHENIA GRAVIS

DISCUSSION

Myasthenia gravis (MG) is an immune mediated disorder of neuromuscular transmission. This condition is characterized by fluctuating weakness and fatigability of voluntary muscles. In the vast majority of cases extraocular muscles are involved. Some patients may also have involvement of the muscles of the tongue, pharynx, and soft palate (dysphagia; difficulty swallowing and dysarthria; slurred speech). Weakness gets worse with any sustained activity and improves after a period of rest.

As mentioned earlier, MG is caused by immune mediated (antibodies) destruction of acetylcholine receptors at the postsynaptic membrane and in some patients it may be associated with a tumor (thymoma) or hyperplasia of the thymic gland. Some patients may have other autoimmune disorders like thyrotoxicosis, SLE or rheumatoid arthritis.

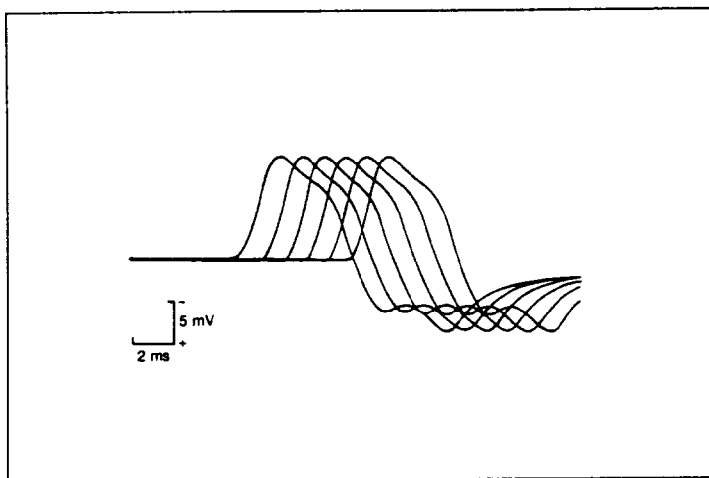
The diagnosis is usually established by a combination of clinical examination (fatigability of limb and cranial nerve innervated muscles), typical decremental response on the repetitive stimulation test, improvement after administration of acetylcholinesterase inhibitors (e.g. tensilon) and presence of antibodies against the ACh receptor in the serum.

Symptomatic treatment consists of administration of anticholinesterase agents like pyridostigmine (Mestinon) which inhibit degradation of acetylcholine in the synaptic cleft.

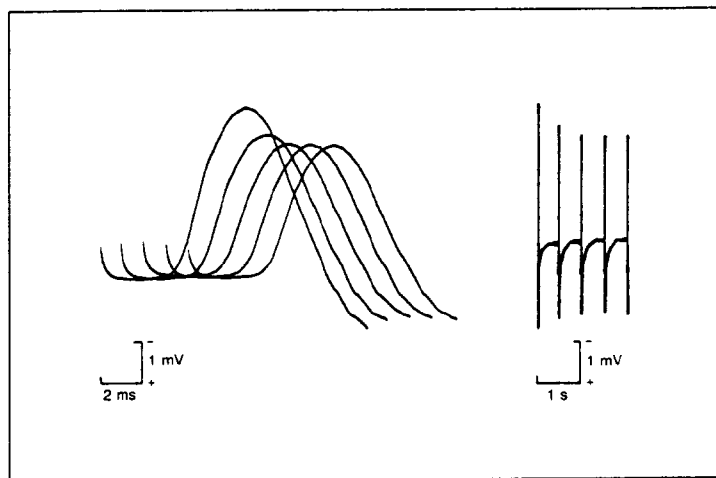
All patients with thymoma have to be treated surgically (an antigenic source for muscle could be in the thymus). Remissions may be achieved by performing thymectomy in some patients (even in those without evidence of hyperplasia). Other forms of immunotherapy consist of administration of corticosteroids or other immunosuppressive medications like azathioprine (Imuran). During the periods of exacerbation patients may be treated, if necessary, by plasmapheresis or high dose intravenous immunoglobulin.

MYASTHENIA GRAVIS

REPETITIVE NERVE STIMULATION
NORMAL RESPONSE



REPETITIVE NERVE STIMULATION
DECREMENTING RESPONSE



From J. Kimura. *Electrodiagnosis in diseases of nerve and muscle.*
F.A. Davis Company 1989.

ANSWER CASE HISTORY III

Severe weakness and sensory symptoms (paresthesias-tingling) affecting all four extremities with absent tendon reflexes and decreased muscle tone are all suggestive of a condition affecting the peripheral nervous system at the level of nerve roots and/or peripheral nerves. A lesion in the brain causing such diffuse weakness and sensory symptoms would have to be extensive and bihemispheric. You would expect some other signs of brain dysfunction (e.g. abnormal mental status, speech abnormality, visual field deficits etc.), muscle tone would be increased (spasticity) and tendon reflexes hyperactive. A lesion of the spinal cord has to be considered. However, there is no sensory level, reflexes are absent, plantar reflexes are flexor and muscle tone is decreased (in a spinal cord lesion, except for acute spinal shock, reflexes would be hyperactive, muscle tone increased and plantar reflexes extensor i.e., a Babinski sign). Sensory symptoms would **not** occur if a lesion selectively affected the neuromuscular junction or muscle.

Fluctuations of the blood pressure and irregularities of the heart rate indicate possible involvement of the autonomic nervous system (B myelinated fibers).

Respiratory failure in this case is most likely caused by severe weakness of respiratory muscles (diaphragm, intercostal muscles).

A nerve conduction study would be most helpful in evaluation of a suspected polyneuropathy and, in fact, it showed diffuse slowing of conduction velocities. These findings are consistent with a demyelinating polyneuropathy.

Many toxic (e.g. arsenic), metabolic (e.g. porphyria) and other etiologies should be considered.

The clinical scenario that was presented to you and the findings on the nerve conduction studies are very suggestive of an acute immune-mediated demyelinating polyneuropathy. This condition is frequently associated with a high protein content in the cerebrospinal fluid.

Lumbar puncture was done and showed normal cerebrospinal fluid (CSF) cell count, however the CSF protein was markedly elevated at 400 mg/dl (normal < 45).

High cerebrospinal fluid protein content is caused by very proximal demyelination at the level of the nerve roots.

Other diagnostic studies including complete blood count, chemistry panel and urinalysis were all normal.

Treatment with high dose intravenous immunoglobulin was initiated and the patient started showing gradual improvement of her strength. She was weaned off the ventilator and discharged to home three weeks after admission to the hospital. Within 3 months her recovery was complete.

GUILLAIN-BARRÉ SYNDROME

DISCUSSION

Guillain-Barré syndrome (GBS), also known in the neurological literature as Acute Inflammatory Demyelinating Polyneuropathy, is an acquired, immune mediated disorder affecting the peripheral nervous system. The pathological hallmark of this condition is **demyelination of peripheral nerves**. Although known as primarily motor polyneuropathy, many patients have evidence of mild sensory nerve involvement. In most cases the demyelinating process also affects the nerve roots. Therefore, this condition is frequently referred to as acute polyradiculoneuritis.

About one-half of patients have a history of preceding acute, usually viral infection.

In typical cases the weakness is symmetric and progresses in ascending fashion (from feet up), and in approximately one-third of cases leads to respiratory failure necessitating ventilatory support. In almost all patients there is early loss of muscle stretch reflexes.

In many cases there are signs of autonomic fiber involvement. These patients may have severe fluctuations in blood pressure (hypo and hypertension) or severe irregularities of the heart rate as well as loss of sweating, gastrointestinal dysmotility and sphincter dysfunction.

Spinal fluid analysis is most helpful in the diagnostic evaluation. It typically shows very high cerebrospinal fluid (CSF) protein content (in some cases as high as 1 - 2 gm/dl) with usually normal or only slightly elevated cell count. The CSF cell count may be much higher in GBS associated with AIDS.

The most important diagnostic test to confirm the diagnosis is the Nerve Conduction Study (NCS) which shows slowing of conduction velocities as well as other changes indicative of peripheral nerve demyelination. GBS has to be differentiated with other neurological conditions, especially acute spinal cord compression (usually brisk reflexes, sensory level, increased muscle tone).

Treatment: Most patients have full recovery provided they receive diligent supportive care. All patients with a suspicion of GBS should be admitted to the hospital since the progression of weakness to respiratory failure may be sometimes dramatic (over 24 hours).

This is an immune-mediated condition. Immunomodulatory treatments like plasmapheresis (plasma exchange) and IVIG (intravenous immunoglobulin) have significantly improved the outcome if initiated early, within the first week of illness.

Prognosis is good in most cases. Approximately 75-80% of patients have complete recovery, 10 percent have mild residual disability and only about 5 to 10 percent of patients have severe disability. Mortality rate is usually less than 3 to 5 percent.

ANSWER CASE HISTORY IV

1). Where is the lesion?

The clinical picture is compatible with a left S1 radiculopathy and most likely it is due to a L5-S1 herniated disc.

2). What would the EMG and needle examination show?

There would be signs of denervation in the S1 muscles, particularly the gastrocnemius, glutei, and the S1 paraspinal muscles. NCV would probably be normal.

3). What diagnostic testing would you order?

To define a herniated disc and make sure that this was not some other problem, an MRI of the spine would be appropriate. Abnormal MRIs of the lumbosacral spine are common and must always be interpreted with respect to the clinical picture.

4). How should this patient be treated and what is his prognosis?

Symptomatic medical treatment is probably as successful as surgical decompression and the patient's condition will improve. Surgery is favored when an active process associated with denervation and weakness is combined with disabling pain. If the EMG does not indicate active denervation (lower CMAP for instance), conservative medical therapy may be more reasonable.

ANSWER CASE HISTORY V

The increased muscle tone, hyperreflexia and positive Babinski sign indicate upper motor neuron (UMN) involvement (Betz cells [cell bodies of corticospinal axons], corticospinal tract, lateral corticospinal tract). Severe, diffuse muscle wasting and fasciculations are suggestive of a lower motor neuron (LMN) involvement (anterior horn cells, motor axons).

In the earlier lectures we learned that when there is a lesion of the LCST and the ventral horn at the same level, there can be no spasticity since the LMNs are dead. In Amyotrophic Lateral Sclerosis not all of the LMNs die at the same time (the disease is progressive). Loss of anterior horn cells leads to atrophy of their target muscles (no spasticity), while those cells that are still functional will cause spasticity in their targeted muscles due to the loss of the LCST input, an upper motor neuron deficit.

The above discussed abnormalities, with normal mental status, normal sensory examination and normal coordination suggest that this condition primarily affects upper and lower motor neurons in the spinal cord.

Possible etiologies would include, among others: primary neurodegenerative process that would affect selectively motor neurons, possible toxic or metabolic conditions (e.g. lead toxicity) causing dysfunction of motor neurons. Space occupying lesions (e.g. a tumor in the cervical spine) have to be ruled out. For example, a tumor in the cervical spinal cord may cause local destruction of anterior horn cells producing muscle wasting, weakness, depressed reflexes in the upper extremities and also compress the lateral corticospinal tract fibers that may cause spasticity, extensor plantar reflexes (Babinski sign) and brisk muscle stretch reflexes in the legs.

MRI (Magnetic Resonance Imaging) of the cervical spine and the brain would help to rule out a structural lesion that might cause the above discussed signs. This was done and was normal.

Nerve Conduction Study (NCS) and Electromyography would be very helpful to evaluate and confirm the suspected involvement of the LMNs and possible other elements of the motor unit.

NCS was normal. Electromyography showed large amplitude, motor units (MUPs) in all muscles tested. As you probably remember from Dr. Lotz's lecture these changes are characteristic of a LMN loss and re-innervation. Fasciculations are also noted.

There are several toxic/metabolic or immune mediated conditions for which you may screen by ordering specific lab tests (e.g. heavy metal toxicity or hyperparathyroidism).

The above presented case is typical of Amyotrophic Lateral Sclerosis.

AMYOTROPHIC LATERAL SCLEROSIS

DISCUSSION

Amyotrophic Lateral Sclerosis (ALS), also known in the United States as Lou Gehrig's disease is a progressive, neurodegenerative disorder affecting primarily motor neurons. This condition usually affects

middle age and elderly individuals. In typical cases there is evidence of both upper and lower motor neuron involvement. The etiology of ALS is unknown. Up to 5 to 10% of cases may be familial. In some of the familial cases a mutation within a Cu/Zn superoxide dismutase type 1 gene on chromosome 21 was found. ALS is a progressive condition leading to severe wasting and weakness of muscles, including bulbar musculature (pharynx, larynx, soft palate and tongue) and death within 3-5 years although some cases may have a more protracted course. ALS has to be differentiated from many other conditions that may affect lateral corticospinal tracts and motor neurons (e.g. spinal cord tumors, metabolic conditions and others) therefore appropriate neuroimaging and laboratory studies should be performed in all new cases. The diagnosis is usually established by a combination of typical clinical and electrodiagnostic findings. Currently there is no specific treatment for ALS.

ANSWER CASE HISTORY VI

A healthy 25 year old woman is brought to the emergency room after being stabbed in the neck. Examination shows:

- 1) left ptosis and meiosis (small pupil)
- 2) weakness of the left upper and lower extremities
- 3) absent left biceps stretch reflex
- 4) other left sided muscle stretch reflexes diminished
- 5) loss of left finger and toe joint position sense (the only joints tested)
- 6) loss of left finger and toe vibratory sensation (the only joints tested)
- 7) loss of pain and temperature sensation below C7 on **right**

1. What is the location of the lesion?

The findings are most consistent with a left spinal cord hemisection or the Brown-Sequard syndrome at the C5 level. The features of the Brown-Sequard syndrome have been emphasized earlier in the course, and its principal findings should be familiar:

- Ipsilateral paresis
- Ipsilateral hyperactive reflexes below the level of the lesion
- Ipsilateral Babinski reflexes and spasticity
- Contralateral loss of pain and temperature sensation two levels below level of lesion
- Ipsilateral loss of vibration/joint position sensation

2. Explain why each of the findings are present.

- 1) Injury to the descending hypothalamic input to the preganglionic sympathetic cells at T1. Axons of such cells exit from the thoracic cord and ascend via the sympathetic chain to synapse in the superior cervical ganglion. Post ganglionic sympathetics then project to the sphincter muscle of the pupil, the orbit and ciliary muscle of the left pupil.
- 2) Lateral corticospinal tract injury at the C5 level caused weakness of the left arm and leg
- 3) The left biceps reflex (C5) is absent due to direct injury to fibers of the reflex arc at that level.
- 4) The other reflexes on the left are probably diminished due to spinal shock. Corticospinal tract signs (hyperactive reflexes, spasticity, and Babinski reflexes) may appear only after resolution of an initial period of spinal shock.
- 5) Joint position sense is lost on the left due to injury to the dorsal columns at C5
- 6) Vibration sensation is lost on the left due to injury to the posterior columns at C5
- 7) The sensory level for pain and cold sensation is typically 2 levels **below** the level of the trauma. Appreciation of light touch is generally preserved on both sides.

3. Why might atrophy of the upper arm develop over time?

Injury to anterior horn cells at or near the level of the lesion can lead to a lower motor neuron syndrome at that level.

DISCUSSION

The Brown Sequard Syndrome and Spinal Cord Syndromes

Spinal cord trauma provided the first clues as to the function of the spinal cord and the manner in which its various tracts are segregated. The fact that severing the cord resulted in immediate paralysis of arms and legs and loss of sphincter control was known from ancient times. First recognized on the field of battle, the observation was skillfully carried into practice by robbers and assassins. It was generally appreciated then, as now, how completely sudden and unexpected, spinal cord trauma might change the life of an individual.

This knowledge was not further refined until Todd and Schiff recognized posterior column function between 1847 and 1858; Brown-Sequard proved their assertions and located other functions when he described the effects of cord hemisection in 1868. The dysfunction is caused by interruption of ascending and descending fibers, and gray cell nuclear complexes within the region of injury.

In North America, acute cord injury has an incidence of about 33 per million; the prevalence of paralysis on the basis of spinal cord injury is nearly 1 per 1,000. Two-thirds experienced the cord injury prior to 35 years of age, most between 20 and 24 years of age. More than 75% are men. The most common levels of injury are at C5-6 and T1-2. The most common cause of spinal trauma is some form of road accident (car, motorcycle, pedestrian, etc.). Other causes (also most common in young men) include sports (biking, diving), industrial accidents, bullets and knives.

Other clinical syndromes that may develop on the basis of trauma, which have been reviewed in lecture include:

1. Transections (findings depend on level):
 - Cord
 - Cauda equina (with or without conus)
 - Conus medullaris
2. Cord concussion
3. Spinal shock
4. Partial cord syndromes
 - Brown-Sequard
 - Anterior Cord syndrome
 - Posterior cord syndrome
 - Central cord syndrome

There is overlap between these syndromes.

The outlook for Brown-Sequard syndrome is variable and, of course, depends on the cause. Inflammatory cases often improve. If the etiology is mechanical cord disruption (e.g. knife) there is usually little improvement. Dysaesthesia (think about what anesthesia means!) may even worsen over time. Blunt trauma-induced Brown-Sequard shows significant improvement in as many as three quarters of cases. Predominantly upper-extremity cases improve more than predominantly lower extremity cases. Cases with greater involvement than just the hemicord Brown-Sequard (e.g. findings in the other side of the cord beyond the dysaesthesia already mentioned) sometimes recover even better than a case of pure Brown-Sequard.

Of all patients with any form of acute cord injury, 40% die within 24 hours. For the rest, long term survival depends on level and severity of lesion, as well as the underlying cause and associated injuries. Quadriplegic patients experience more than ten-fold and paraplegics at least five-fold greater mortality than the general population. Among survivors, some experience improvement, except where the cord has been completely transected.