

## CLINICAL VIGNETTE

### An 18-year-old woman with medically intractable seizures

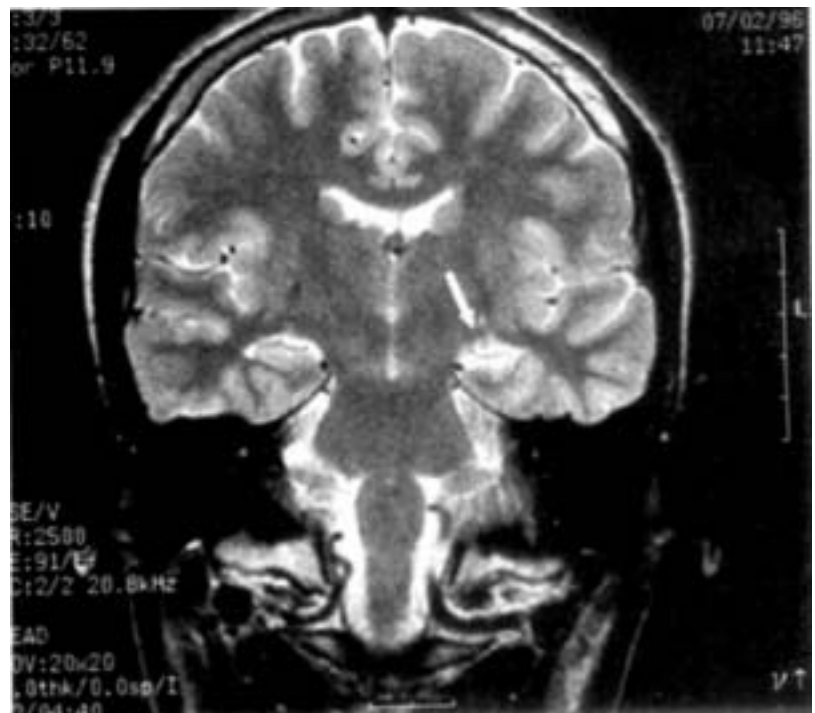
An 18-year-old woman presented for evaluation of seizures that were not controlled by medical therapy. At the age of 6 months she was hospitalized with a fever and seizures, and was reported to have encephalitis. She lost motor and language developmental milestones, but these were gradually regained and she was treated for a year with phenobarbital and was without recurrent seizures. The phenobarbital was tapered at age 2 but at the age of 6 years she again experienced seizures, which occurred at low frequency until puberty, when the seizure frequency increased to two to three per day. The seizures were characterized by an initial aura of tightness in the head and chest and sweaty palms, followed by impaired consciousness, lip smacking, hand rubbing, and unresponsiveness. During a seizure she was unable to talk but could hear, and could not fully process information. She was treated with a variety of anticonvulsants, including phenobarbital, carbamazepine, phenytoin, valproate, and lamotrigine without significant success in seizure control. Her medical history was otherwise unremarkable. There was no family history of seizures.

*Physical Examination:* Vital signs: normal. Bedside mental status examination: no significant abnormalities. Neuropsychological testing: full-scale IQ of 97, performance IQ of 97 and a verbal IQ of 96; mild difficulty acquiring certain types of information and some difficulty with uncued recall. Speech: normal. Cranial nerves: normal with only minimal, unsustained nystagmus on lateral gaze. Motor and sensory examinations: normal. Muscle stretch reflexes: normal. Coordination and gait: normal.

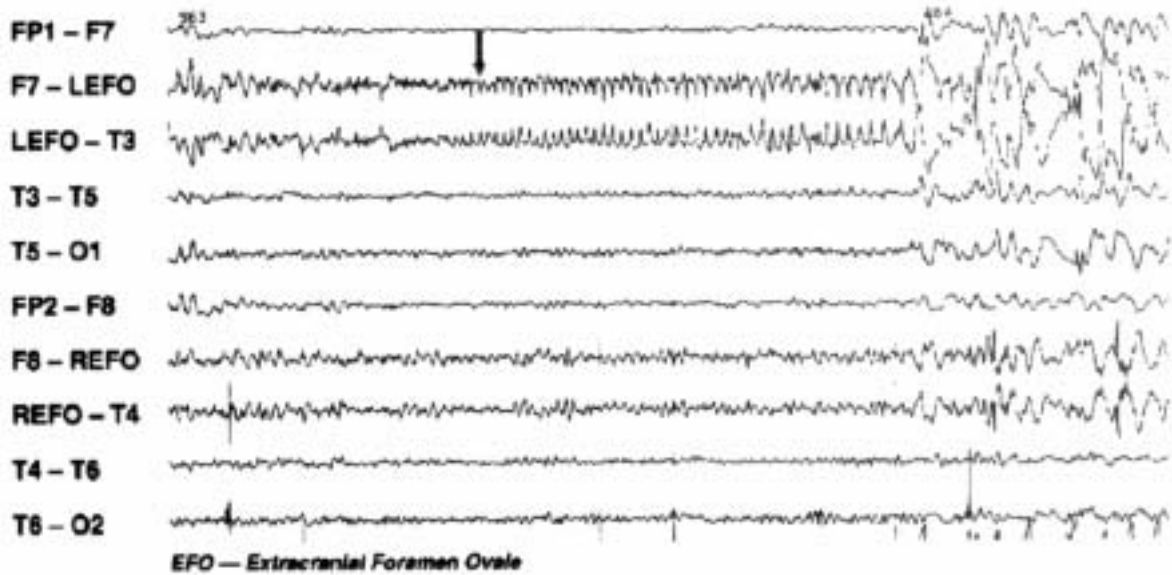
*Stop and Consider:* What is the classification of her seizures according to the International Classification of Seizures? How should she be treated at this point?

*Laboratory Findings:* CBC, serum chemistries with liver and renal functions, PT, PTT, ESR: normal. MRI: see figure, shows left hippocampal atrophy and increased T2 signal. Interictal EEG: left temporal sharp and slow wave activity suggestive of left temporal onset of seizures. Continuous video-EEG monitoring: several seizures captured. EEG, see figure, *next page*, shows left mesial temporal (EFO) onset. Interictal positron emission tomography (PET) scan: hypometabolism of the left temporal lobe.

*Diagnosis:* Medically intractable partial complex seizures associated with hippocampal atrophy.



In this patient, MRI, prolonged video-EEG monitoring study, and PET scan were consistent with a left mesial onset of seizures and invasive EEG recording was not necessary. Preoperative Wada's test (intracarotid amytal injection) demonstrated left hemisphere language dominance and adequate right hemisphere memory function. She underwent left anterior temporal lobectomy and did very well postoperatively in terms of memory function with no change from her baseline findings, and became seizure-free. An attempt to taper by antiepileptic drugs was followed by breakthrough of seizures but reinstatement of antiepileptic medications again resulted in complete seizure control.



## EPILEPSY

### Epilepsy: anatomic and physiologic correlates

**Epilepsy is the condition of chronic recurrent seizures that occur because of an inherent problem with brain hyperexcitability. Seizures are the phenomenon of abnormal synchronization of cortical neurons that results in a change in perception or behavior.**

There are many causes of seizures that include intoxications by drugs that alter neuronal circuit excitability (e.g. cocaine or drugs that block synaptic inhibition), withdrawal from certain drugs (e.g. alcohol), or a wide variety of metabolic derangements (low glucose, low calcium, hepatic or renal failure). Up to 8% of the population will have a seizure at some time in their life.

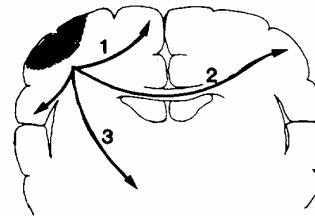
**Epilepsy, however, is a condition in which seizures occur without definite provocative factors.** About 0.5% of the population has epilepsy. There are many causes of epilepsy and the term does not refer to a **specific disease** but a **condition**.

**We classify seizures in terms of the anatomic correlate of the abnormal synchronous electrical activity.** In the broadest sense seizures are either **focal, starting in one region of the cortex, or generalized at onset, beginning diffusely throughout the cortex and driven by thalamocortical pathways.** Focal seizures may spread to become secondarily generalized seizures and the anatomic substrate includes corticothalamic, thalamocortical, association fibers, and callosal connections.

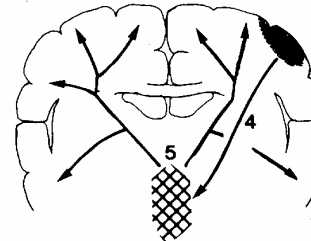
**Focal seizures** are termed **partial seizures** and the symptomatology is dictated by what area of the cortex is activated. **When these seizures do not affect consciousness, they are referred to as simple partial seizures.** If the motor cortex is involved, then the seizure consists of rhythmic motor activity contralateral to the focus. Correlating the behavior of seizures and the associated lesion or electrical abnormality has greatly enhanced our understanding of cortical anatomy. In fact the homunculus that you are all familiar with was a product of a neurosurgeon (Wilder Penfield) stimulating the brain of awake patients undergoing surgery to try and remove the area of abnormality responsible for their seizures.

#### A FOCAL SEIZURE

##### 1 Spread

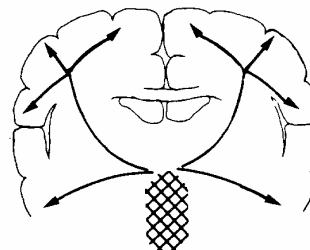


##### 2 Secondary Generalization



- 1 = association fibers
- 2 = callosal connections
- 3 = corticothalamic fibers
- 4 = corticothalamic fibers
- 5 = thalamocortical fibers

#### B PRIMARY GENERALIZED SEIZURE



Partial seizures, particularly those that begin in the limbic system may begin with various emotional feelings like fear and may also cause déjà vu sensations. Limbic seizures often spread to involve important substrates for consciousness without producing frank unconsciousness.

**When a focal/partial seizure involves impairment of consciousness the seizure is referred to as a complex partial seizure.** The patient does not remember what they do during the seizure, usually there is significant dysfunction of the hippocampi during the seizure that blocks memory formation. During this period, usually lasting 1-2 min, a variety of automatic behaviors may occur and are termed automatisms (an automatic and apparently undirected, nonpurposeful behavior that is not consciously controlled.)

## Classification of Seizures

### I. Partial


- A. Simple: consciousness unaffected, symptoms refer to cortex involved
- B. Complex: consciousness impaired, amnesia
- C. Secondarily generalized, thalamocortical and other pathways involved

### II. Generalized

- A. Tonic-clonic
- B. Absence
- C. Tonic
- D. Clonic
- E. Myoclonic
- F. Atonic

Any seizure that begins in one area of the cortex (partial or focal) may spread and the seizure may evolve into a **generalized** tonic-clonic or **grand mal** seizure. The seizure spreads via the anatomic connections that you have learned about and include connections to adjacent gyri, to the opposite hemisphere via the corpus callosum, and to the thalamus.

**Partial seizures are associated with underlying regions of abnormal cortical excitability that results from any of a great many insults. The EEG correlate of partial seizures is the interictal (between seizure or ictus) spike or sharp wave that is localized to a region of the scalp.** When a seizure occurs, a more sustained abnormal rhythm that consists of rhythmic slow and spike or sharp activity occurs in the EEG. As the seizure spreads, other brain regions reflect abnormalities in the EEG.



A focal interictal spike in the LEFT frontotemporal region. This is the EEG hallmark of parietal seizures. Odd numbers refer to the left and even the right hemisphere.

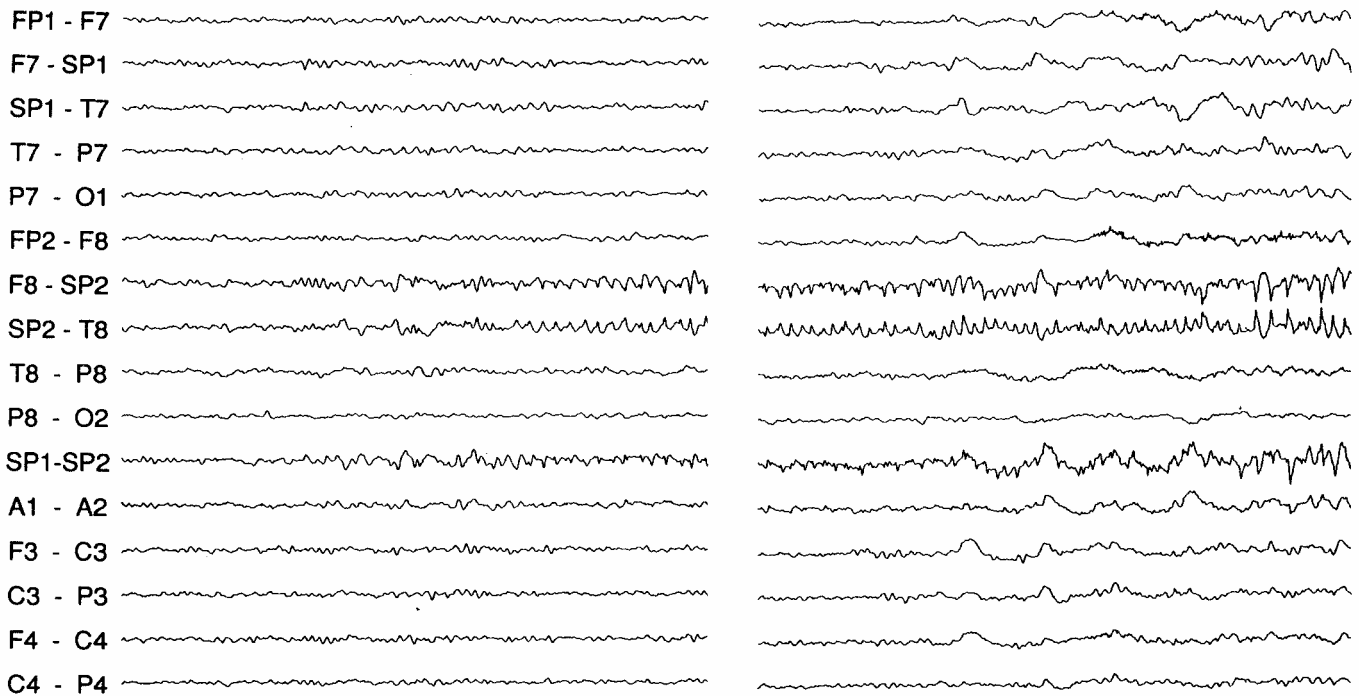
interictal spike

## TEMPORAL LOBE EPILEPSY COMPLEX PARTIAL SEIZURE

100  $\mu$ V  
1 SEC.

- 14 SECONDS

CLINICAL ONSET

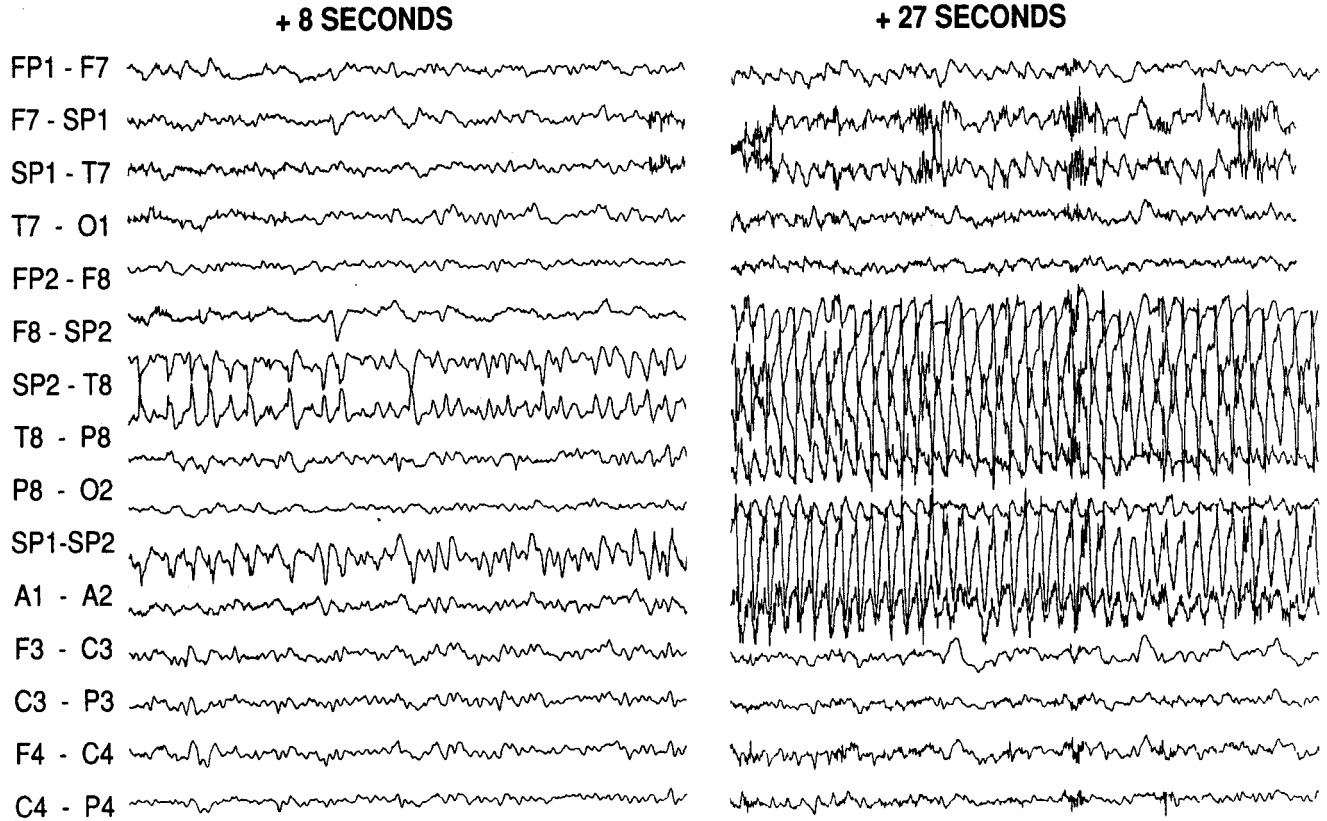


Thirty-one-year-old woman with complex partial seizures since age 5 years. Fourteen seconds before clinical onset, an EEG seizure pattern was maximal at the right sphenoidal electrode (SP2). The sphenoidal electrode is located near the foramen ovale and the medial temporal lobe.

Note the build up of rhythmic EEG activity from the right SP2 electrode.

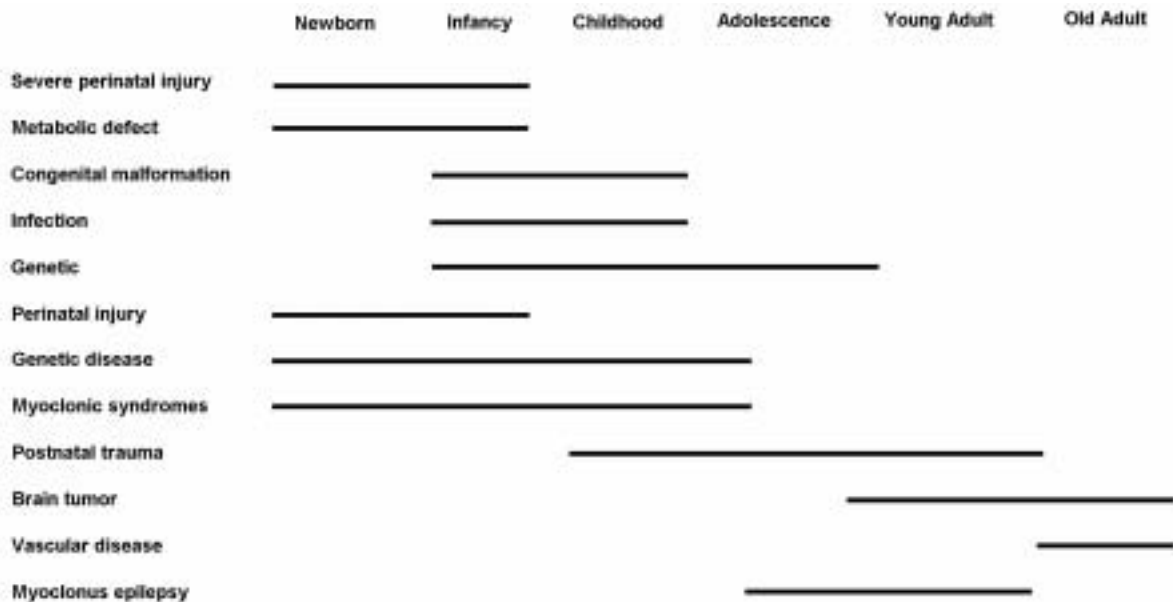
# TEMPORAL LOBE EPILEPSY COMPLEX PARTIAL SEIZURE

100  $\mu$ V  
1 SEC.



Clinical features included staring, unresponsiveness, and oral automatisms.

**Note the spread of activity to effect other electrodes.**

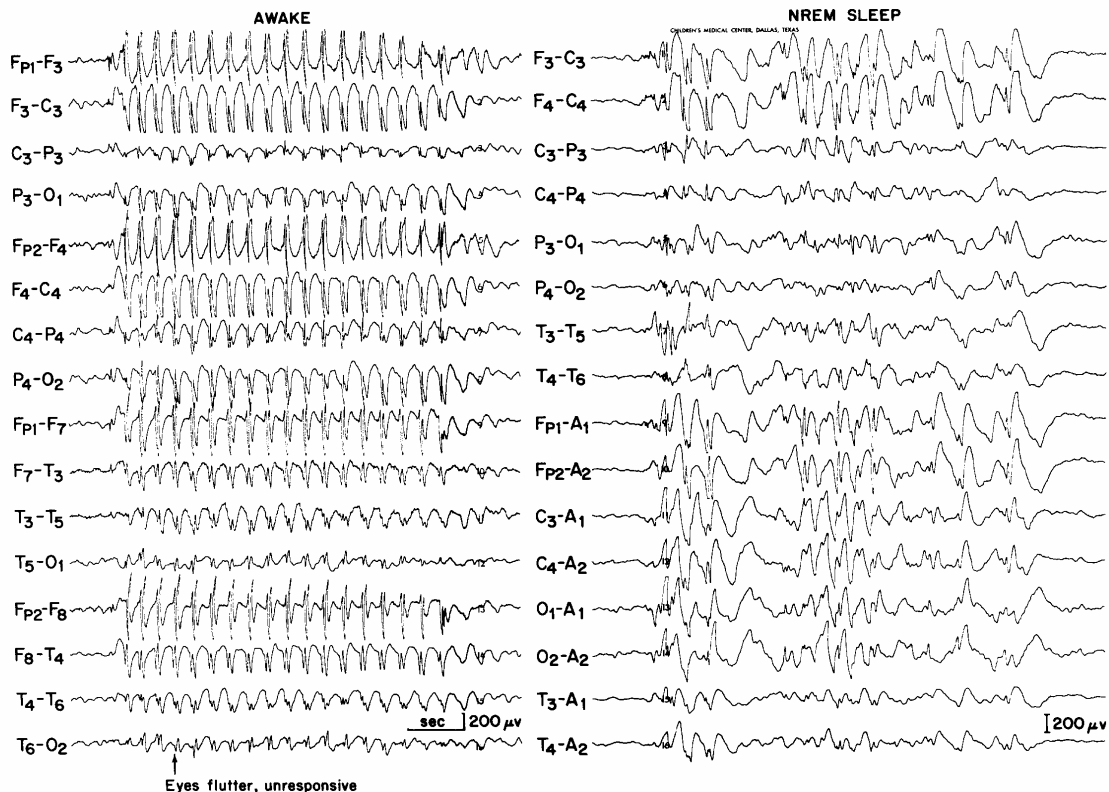


**Common causes of seizures by age**

**Generalized seizures are either associated with a genetic predisposition for abnormal excitability inherent to an instability in the thalamocortical connections or result from a severe dysfunction of neuronal activity from multiple lesions or inherited neurologic storage diseases.**

**Generalized seizures begin all over the brain at once and are a product of an instability of the thalamocortical circuitry.** The most intense generalized seizure is a tonic-clonic seizure that consists of a tonic phase lasting up to 20-30 seconds followed by rhythmic clonic muscle activity lasting another 30-60 seconds. After a tonic-clonic seizure the patient has post-ictal unresponsiveness that evolves to a period of consciousness and confusion. Other generalized seizures are less dramatic but may be equally problematic. **Absence seizures** (petit mal) are associated with high voltage 3 Hz spike (versus a normal 8-12Hz "awake" EEG) and wave activity associated with rather minor behavioral changes. During an absence seizure, the person may stare, blink their eyes at 3/sec, and will not respond to verbal stimuli. The seizure only last 15-20 seconds and the person is **amnesic** for what ever happens during the seizure. Afterwards the EEG and the person return to normal without postictal changes.

Myoclonic seizures are repetitive jerks of axial and limb musculature that are usually brief and also associated with a generalized spike-wave pattern. Seizures may also be generalized and associated with loss of motor tone (atonic seizures) or marked increase in tone (tonic seizures). These latter two seizures are also brief, lasting seconds, and associated with a desynchronization or decremental response in the EEG.



Three-hertz spike-and-slow-wave complexes. This 7-year-old girl had had absence seizures for 6 months. Her maternal grandmother and a cousin had had tonic-clonic seizures. **Left:** While awake, the child has a spontaneous absence seizure (arrow). The technologist observed that the child's eyelids fluttered, that she did not respond to a test phrase, and that after the absence seizure she did not recall the test phrase. **Right:** Stage II NREM sleep (see text for effects of sleep).

**The thalamocortical pathways that mediate these seizures are the same pathways that modulate sleep-wake cycles.** In fact the generators of sleep spindle activity are the same that lead to absence seizures. When not treated, people with absence seizures have very few spindles but instead have spike-wave activity. With treatment, the spike-wave abnormalities are replaced by normal spindle activity.

We also try to classify the syndrome associated with a patient's epilepsy. Seizures that begin focally are considered to be localization related epilepsy and the characteristics of the seizure relate to the area of where the seizures begin, e.g. from the frontal, temporal, occipital, or parietal lobes. Many of the generalized seizures that have a definite inherited predisposition may remit with maturation, and the clinical picture is of a developmental syndrome.

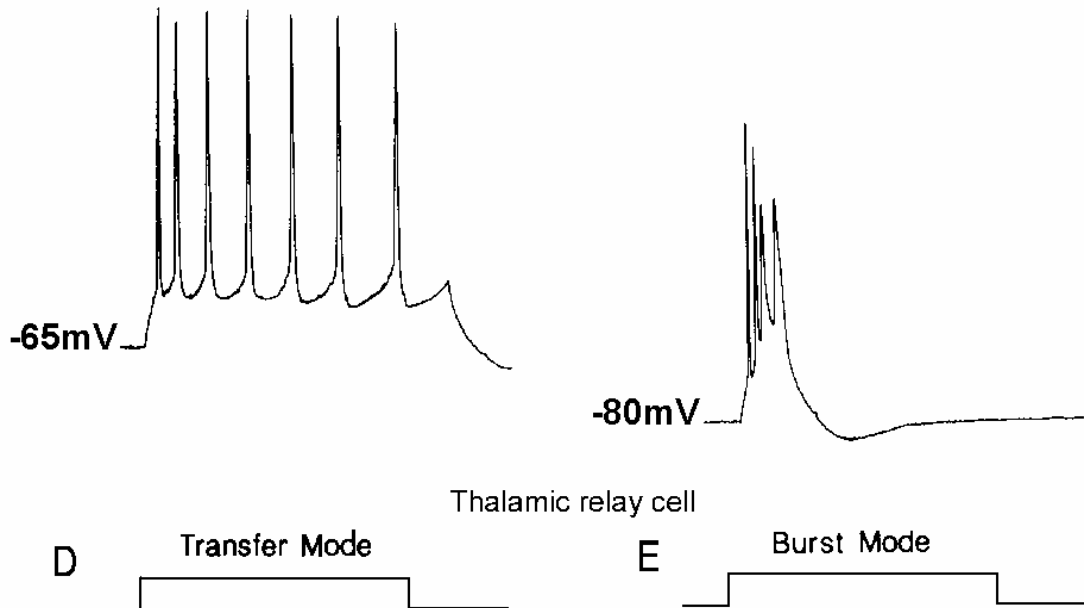
Our treatment of seizures depends on the type of seizures. **In general, seizures appear to begin because of an imbalance between synaptic inhibition and excitation.** For **generalized** seizures this imbalance exists in **thalamocortical circuitry**. An effective drug for absence seizures is ethosuximide, which **reduces** low threshold calcium currents. **In partial seizures the imbalance in inhibition and excitation is localized to a specific cortical area.** The drugs we use to treat these seizures tend to decrease the ability of neurons to fire action potentials at a high rate (eg. phenytoin or carbamazepine). Another treatment strategy is to increase inhibition by using drugs that enhance GABA's function (eg. phenobarbital or diazepam derivatives). Recent drugs have also been targeted to blocking GABA uptake or enzymatic degradation. In the future, drugs may be targeted to specific glutamate receptors that may be particularly important for seizure generation.



**READ ON ONLY IF YOU ARE INTERESTED.  
I WILL NOT ASK YOU ANY QUESTIONS ABOUT WHAT FOLLOWS.**

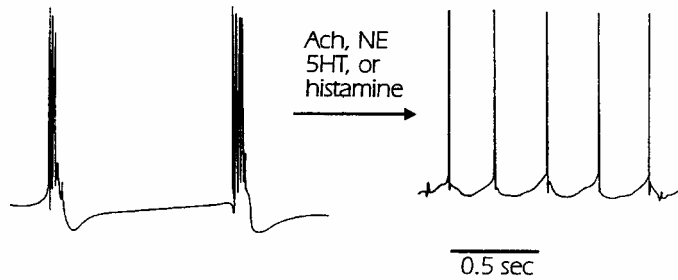
**Thalamocortical circuitry in sleep-wake physiology**

The interaction between the intralaminar nuclei of the thalamus and the cortex defines our state, i.e. are we awake or sleep, and what state of sleep are we in. The thalamic relay neurons, those neurons that project to the cortex, have membrane properties that define how they fire at different membrane potentials. When the neurons have a membrane potential of around  $-80\text{mV}$ , they fire in a bursting mode. The burst firing mode results from a low threshold voltage dependent calcium current. At a membrane potential of about  $-65\text{mV}$ , they fire in a more regular mode of single action potentials. At this membrane potential the low threshold calcium current is inactivated (similar to the inactivation of sodium current that occurs with depolarization).

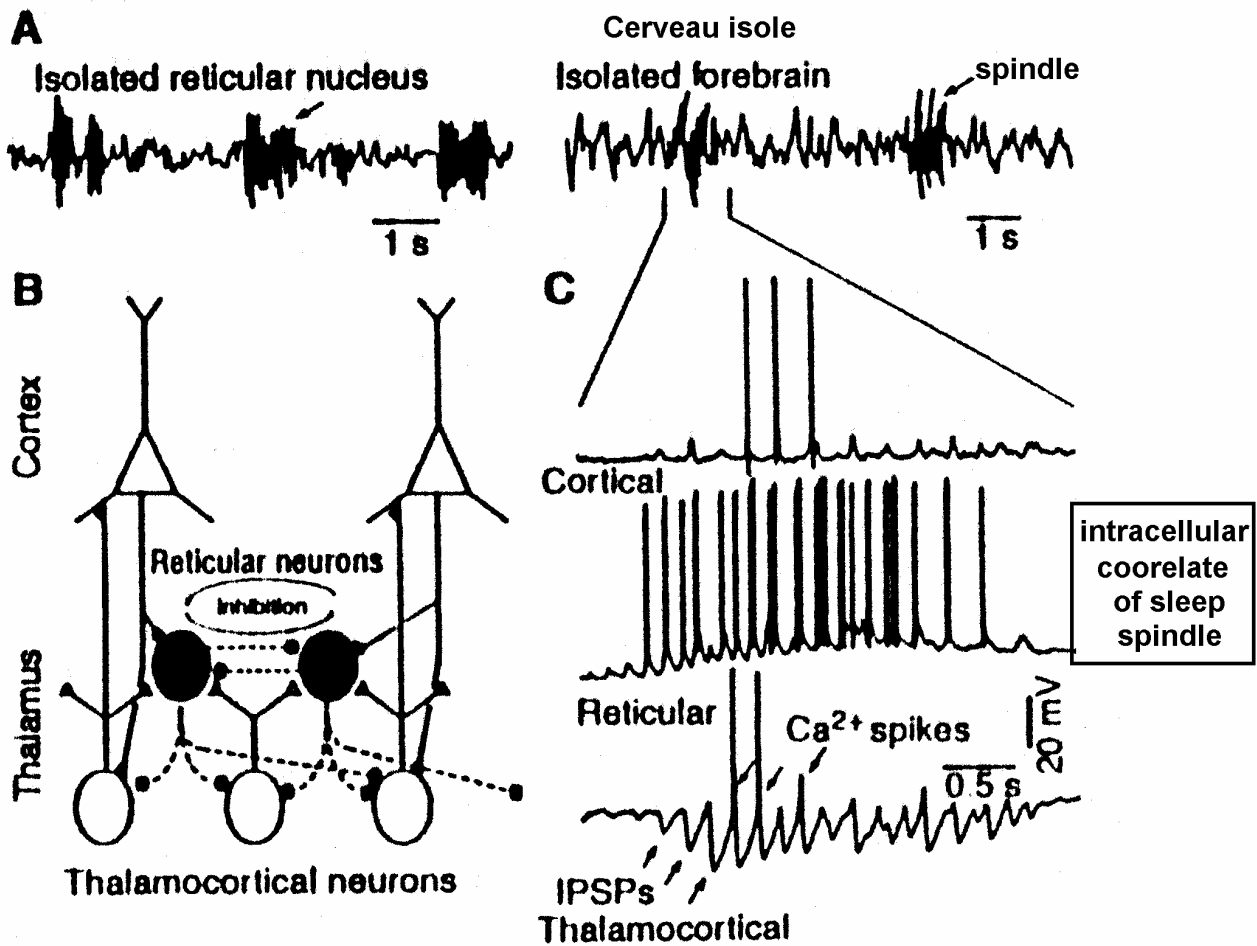


The transfer mode of neuron firing is the basis for an awake, alert state. A number of neurotransmitters or modulators can produce depolarization so that the membrane potential is around  $-65\text{mV}$ . The membrane potential can be depolarized by closing potassium channels. Neurotransmitters like acetylcholine, norepinephrine, or histamine will favor the transfer mode of firing).

Thalamic relay neurons have two modes of firing:  
 Burst mode (slow bursts of action potentials) and  
 Tonic mode (steady trains of spikes).  
 Certain transmitters move the cells into the Tonic mode.



The burst firing mode is characteristic of stage II and III sleep and the bursting of the relay neurons drive the generation of sleep spindles. The relay neurons are hyperpolarized by GABAergic input from the reticular neurons. GABA acts at both GABA<sub>A</sub> and GABA<sub>B</sub> receptors and the GABA<sub>B</sub> receptor activation changes the relay mode to a burst firing mode. Because none of these neurons function in isolation, the synaptic circuitry involving the relay neurons, the reticular neurons, and cortical neurons allow for oscillations to occur. Deep sleep characterized by slow waves is associated with even more hyperpolarization of the relay neurons and a slower 1-2 Hz oscillation. REM sleep is associated with a return to a relay mode of firing.



**Problem Solving**

1. Seizures that begin in one area of the cortex are called:
  - A. generalized seizures
  - B. absence seizures
  - C. primary seizures
  - D. partial seizures
  - E. none of the above
  
2. Generalized seizures:
  - A. are not localized at their onset
  - B. predisposition is often inherited
  - C. occur because of thalamocortical circuitry instability
  - D. all of the above
  - E. none of the above
  
3. Partial seizures that impair consciousness:
  - A. are called a complex partial seizure
  - B. patient remembers what they do during seizure
  - C. never evolve to tonic-clonic
  - D. do not involve the limbic system
  - E. none of the above
  
4. Any of these mechanisms may have anti-epileptic actions except:
  - A. increased synaptic inhibition
  - B. decreased synaptic excitation
  - C. decrease of a low threshold calcium current
  - D. decrease in ability of neuron to generate action potentials
  - E. enhancement of glutamate receptor numbers on cortical neurons
  
5. Which of the following statements is **FALSE** regarding complex partial seizures?
  - A. begin with a déjà vu sensation
  - B. originate in the temporal lobe
  - C. never lead to generalized tonic-clonic seizures
  - D. involve limbic structures
  - E. may result from head trauma
  
6. Consciousness is normal during which type of seizure?
  - A. generalized tonic-clonic
  - B. absence
  - C. complex partial
  - D. simple partial
  - E. none of the above

Answers

1. D 2. D 3. B 4. E 5. C 6. D

## Consciousness: Neuroanatomy, physiology, and pathophysiology

We all know what consciousness is and recognize that we are conscious beings. But what makes us conscious? In this lecture we will explore the anatomy, physiology and pathophysiology of consciousness. The goals are to define how abnormalities of consciousness and its regulation are symptoms of disease processes. The student should be able to identify key anatomic substrates of consciousness, how their activity defines changes in consciousness, and how injury to these anatomic substrates produce conditions of abnormal consciousness.

*What is consciousness?* I know that if you are reading this sentence you are conscious. In simplest terms, **consciousness is the awareness/perception of self and environment**. It is a state in which we can respond appropriately to our environment. If you are starting to drift off to sleep as you read these notes, your level of consciousness is decreasing. A strong afferent stimulus like a door slamming or a fire alarm will help you regain your consciousness. In more philosophical terms, consciousness represents a condition of self-awareness that includes abstract thought processing. Modern neuroscience believes that consciousness is produced by our brain's activity.

### Coma: Pathologic Unconsciousness

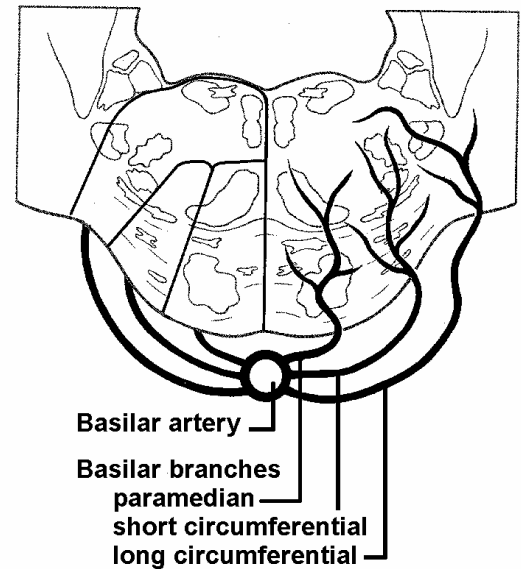
**The condition of unconsciousness from which a patient cannot be aroused is termed coma.** If the patient arouses but quickly falls back into unconsciousness we call them stuporous. Stupor and coma have many causes and patients need to be thoroughly evaluated as to cause. The anatomy of coma must include dysfunction of one of the following: both cerebral hemispheres, the thalamus, or the ascending reticular activating system (ARAS).

The most common causes of coma are metabolic derangements. We term this condition **encephalopathy**. Some of these comatose patients are comatose because of a drug overdose. The most common drugs include barbiturates and alcohol that enhance the GABA<sub>A</sub> receptor function. GABA is the main inhibitory neurotransmitter in the brain. Interestingly most anesthetics also act at the GABA<sub>A</sub> receptor. Other drugs that cause coma are opiates and compounds that have an anticholinergic effect. Remember that our awake and alert state is in part due to cholinergic drive on thalamic and cortical neurons.

Other patients who are comatose because of metabolic problems have endogenous metabolic abnormalities. Neurons are affected by a variety of metabolic abnormalities and cause them to function abnormally. These include encephalopathy following hypoxia, because of organ failure (liver, kidney, or endocrine), and because of electrolyte or glucose disturbances.

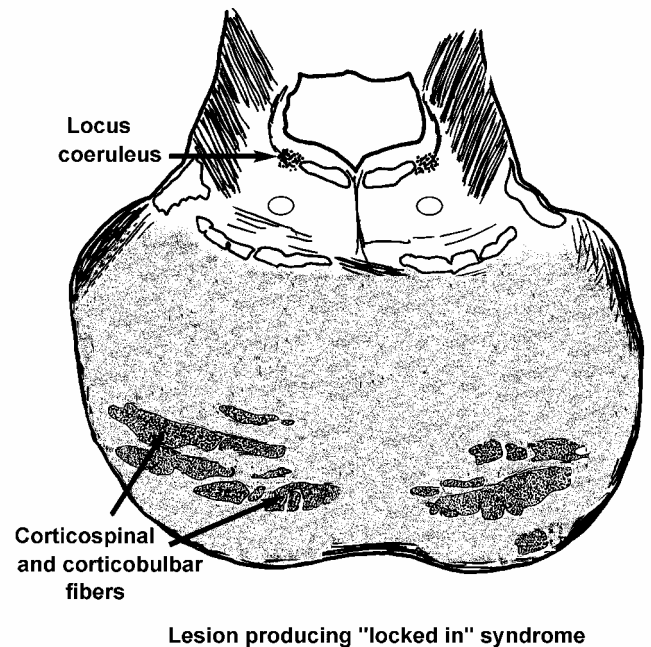
Patients with metabolic coma do not have focal neurologic findings unless they are due to pre-existing conditions. They may have hypo- or hyperreflexia but the findings are symmetric. Babinski signs may be present, but are usually bilateral. These patients have coma because of a diffuse disturbance of cortical, thalamic and ARAS. The EEG shows slowing and a variety of periodic patterns.

Comatose patients also have lesions in the brain stem. The most common cause of these lesions is thrombosis of the basilar artery. Their coma results from injury to the ARAS.



One condition you should be familiar with is called the **"locked-in" syndrome**. In this condition there is a lesion, usually produced by a stroke, in the ventral pons that cuts off the corticospinal and corticobulbar tracts bilaterally (see figure below). The ARAS is spared (travels in the tegmentum) so that the patient is conscious; however, the patient cannot move or speak. Communication can be maintained by having the patient open or close their eyes in a coded fashion. The EEG is normal since the ARAS is not damaged. It is important to recognize the existence of the "locked-in" state and communicate with the patient appropriately.

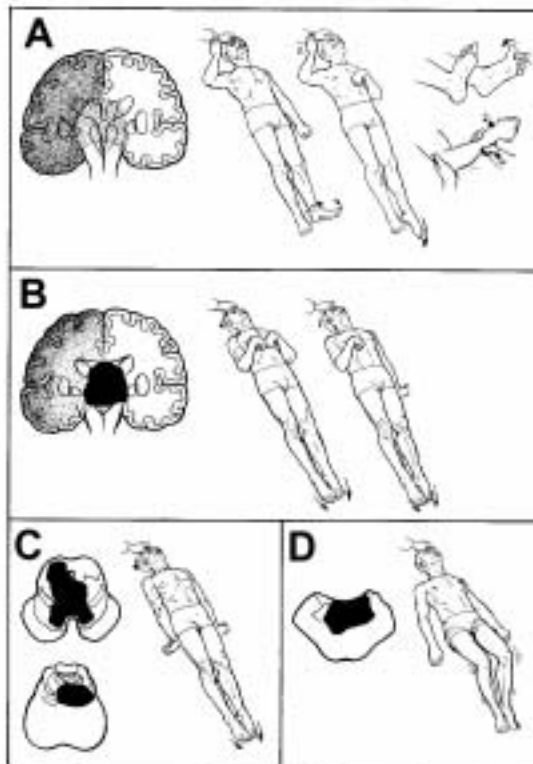
Brain stem damage resulting in coma also occurs following supratentorial (structures lying above the tentorium cerebelli) lesions. In the following (A, B, C, D) you can see the effects of a cortical lesion/mass that eventually causes compression/damage/death of most of the diencephalon and brain stem.



## SCENARIO A

Let's suppose a subarachnoid hematoma has affected the right cerebral hemisphere and diffusely affected the thalamus and hypothalamus, perhaps more on the right. (We understand that this diagram is very schematic!!). This causes a left hemiplegia. The effect of the lesion on the thalamus induces coma. The left upper arm is flexed and the left lower limb is extended. This should sound familiar. This posturing of the limbs in which coma is also present is called **DECORTICATE RIGIDITY**. Both pupils are small (meiosis; sound familiar?) as the hypothalamus is damaged on both sides and thus the descending sympathetics to T1-L2 are interrupted. The pupils are, however, reactive to light because the pathways for the pupillary light reflex are intact. Caloric stimulation (remember COWS!) is normal at this time as CN VIII is caudal and the connections of the VOR are intact. Interestingly, when you excite the circuitry of the VOR you don't get the snap-back second movement of nystagmus. This is because the fast movement is dependent upon a normal frontal eye field, i.e., cortex. These descending projections to the PPRF are damaged bilaterally in the internal capsule. Since the fast movement is gone, warm water into right ear (for example) will result in movement of the eyes left. Moreover, if you move the patient's head to the right (be sure that the cervical spine is OK) the eyes will turn to the left. This is called **DOLL'S EYES**.

**A**



### DECORTICATE RIGIDITY

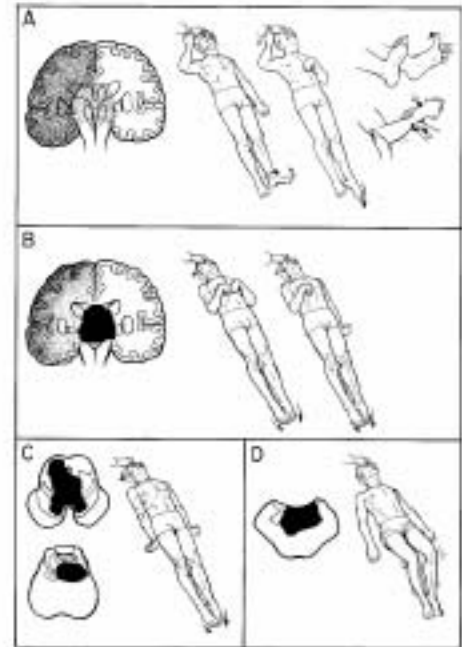
Postural result  
 more activity in biceps and quads  
**FLEXION OF UPPER LIMB**  
**EXTENSION OF LOWER LIMB**  
 (like CST lesion)

**SCENARIO B**

A little later in the scenario, there is compression/damage/death to deeper structures. The cortex, thalamus and hypothalamus are more affected and begin to comprise a central mass or **central herniation** that pushes on the midbrain. The **decorticate rigidity** now involves all four extremities. The pupils will usually be mid-sized and unreactive to light (fixed). This is due to the bilateral interruption of the descending autonomics and stretching of CN IIIs. Since CN III is damaged, the action of the VOR is affected. Thus stimulation of the right ear with warm water will result in movement of the left eye, (right vestibular apparatus, right vestibular nuclei, left PPRF and left LR6 are fine). However, the right medial rectus cannot contract as CN III is shot. **NO DOLL'S EYES.**

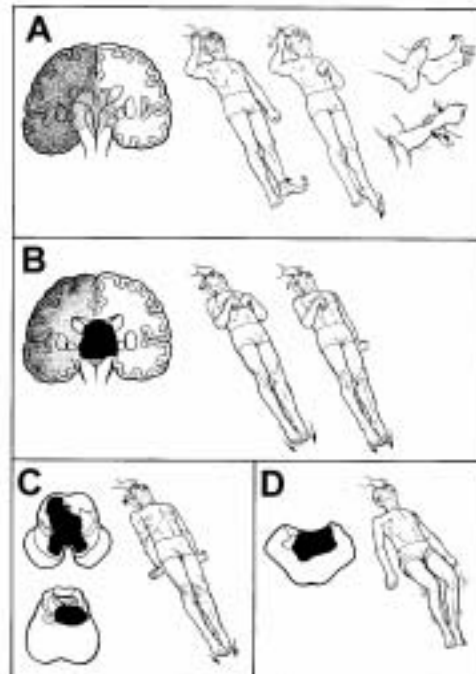


**DECORTICATE RIGIDITY**  
**FLEXION OF UPPER LIMB**  
**EXTENSION OF LOWER LIMB**



**SCENARIO C**

Now the lesion has moved down to include the midbrain, at the level of the junction of the superior colliculus and inferior colliculus. The coma now includes what is called **DECEREBRATE RIGIDITY**. All **four extremities are extended**. The pupils are in mid-position and unreactive to light (fixed). This is due to the lesion damaging both descending autonomic pathways and the CN IIIs (fibers and nuclei). Since CN III is damaged, the action of the VOR is affected. Thus stimulation of the right ear with warm water will result in movement of the left eye, (right vestibular apparatus, right vestibular nuclei, left PPRF and left LR6 are fine). However, the right medial rectus cannot contract as CN III is shot. **No DOLL'S EYES**



**DECEREBRATE RIGIDITY**

Postural result

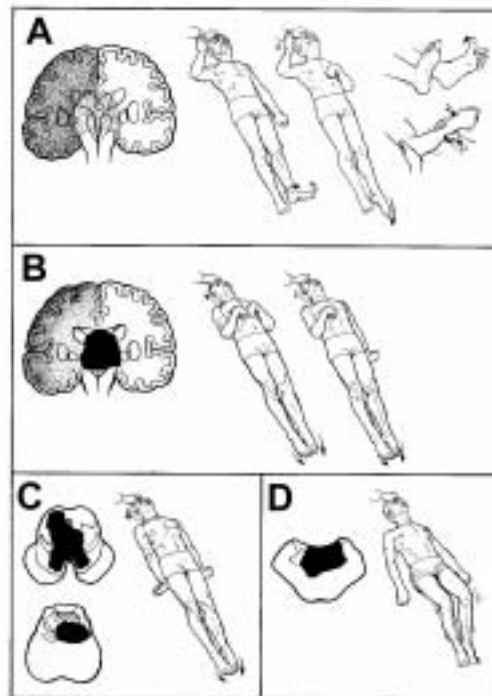
**EXTENSION OF UPPER  
 and LOWER EXTREMITIES**



## SCENARIO D

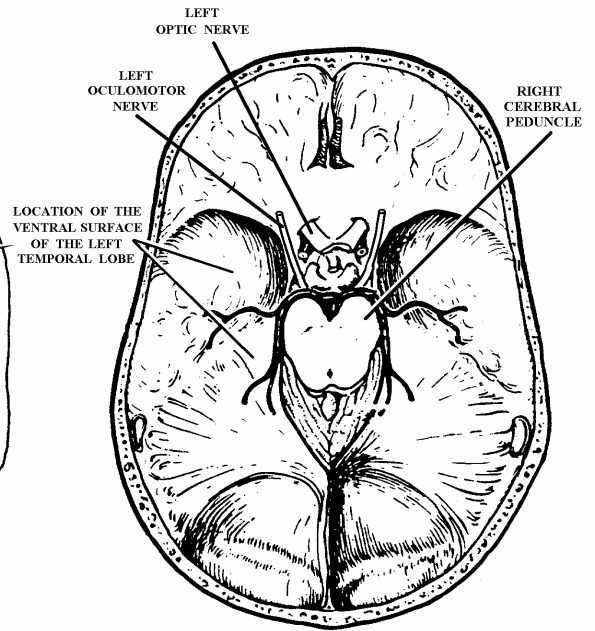
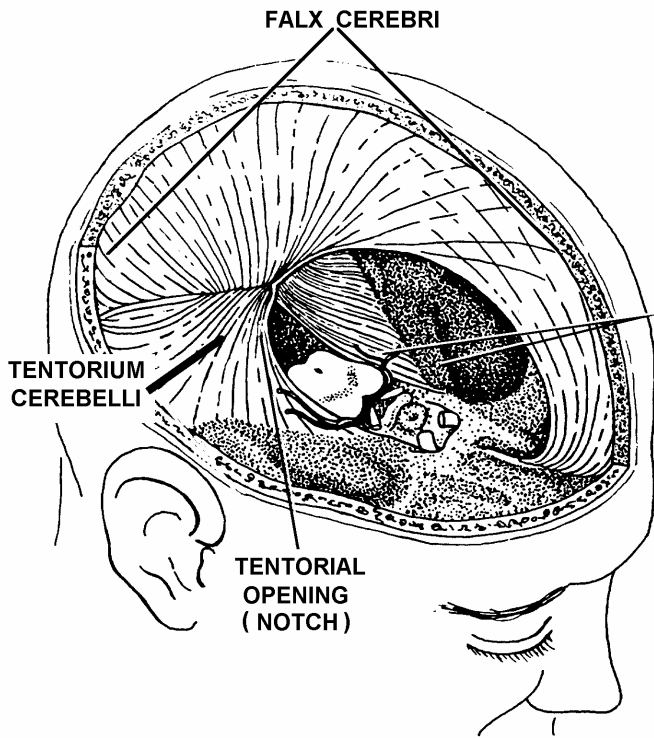
Here the lesion extends into the medulla. There are no extreme positions of the extremities. The pupils are still in midposition (descending autonemics and CN III are shot!) and fixed (remember, the lesion now runs the length of the brainstem). Since the vestibular nerves/nuclei are now damaged, the VOR does not work.

**D**

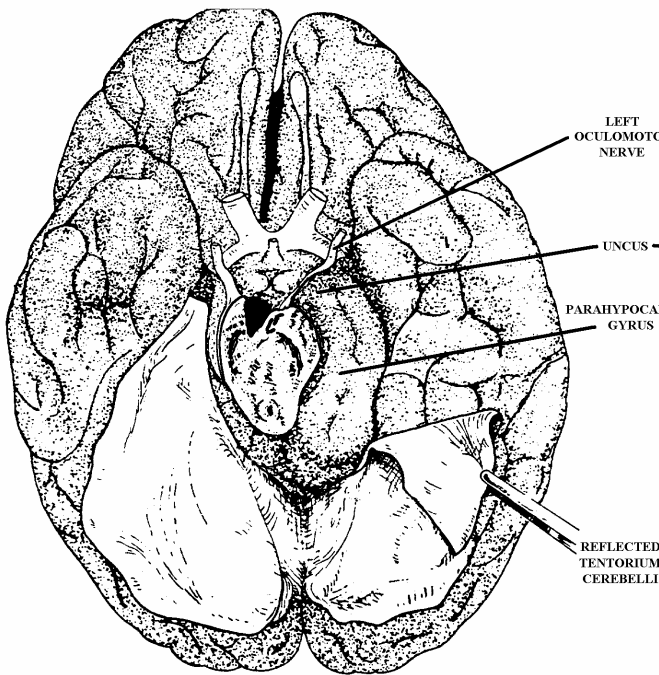


**Lesion in the medulla**  
**Postural result**  
 neither flexion nor extension  
 "it's a wash"

**Uncal herniation** also results from supratentorial pressure. This occurs when the uncus and medial temporal lobe structures herniate through the tentorial notch. The local anatomy of this region includes CN III. Because fibers that produce pupillary constriction are on the outside/periphery of CN III, pupillary dilatation and a sluggish response to light are the first signs of CN III nerve compression. (It is interesting that in a diabetic mononeuropathy of CN III, the most central fibers (associated with the somatomotor/eye muscle innervation) are affected first, sparing the peripherally located parasympathetic fibers). The left herniation causes the left cerebral (smart) peduncle to be damaged; this results in a contralateral/right hemiplegia in addition to the ipsilateral/left dilated pupil. In some cases the pressure distribution results in the opposite (right) cerebral peduncle being compressed against the tentorium. This results in hemiplegia ipsilateral to the CN III dysfunction. When the opposite (to the herniation) cerebral peduncle is compressed against the taunt free edge of the tentorium cerebelli, a "notch" in the peduncle occurs. This is called **Kernohan's notch**. Most herniations cause twisting/compression/stretching of the brainstem that results in damage to penetration branches of the basilar artery. These are called **Duret** hemorrhages.

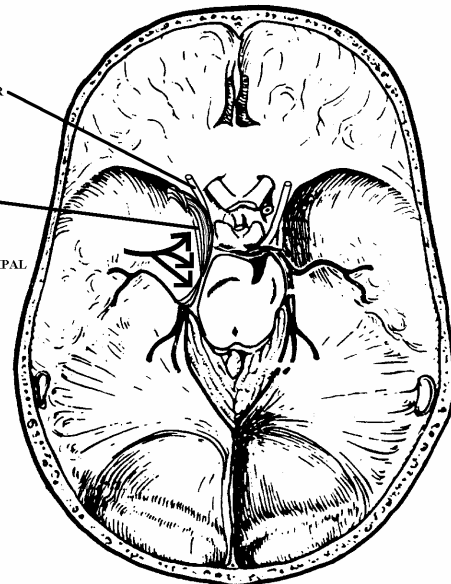


DORSAL VIEW OF DURAL MEMBRANES (CORTEX HAS BEEN REMOVED)



VENTRAL VIEW OF HERNIATED CONDITION

RIGHT LEFT



DORSAL VIEW OF DURAL DISTORTION FOLLOWING UNCAL HERNIATION

LEFT RIGHT

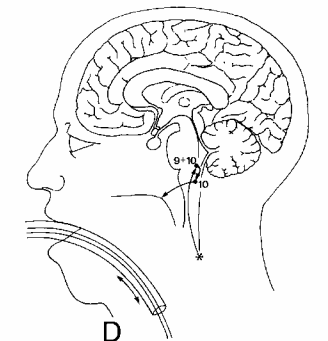
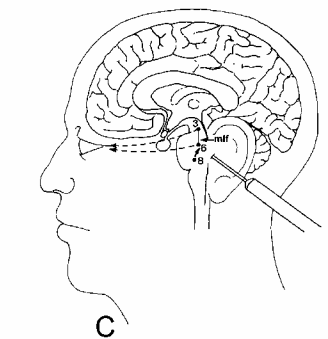
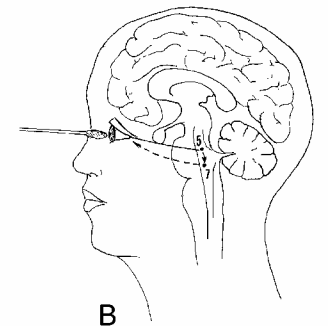
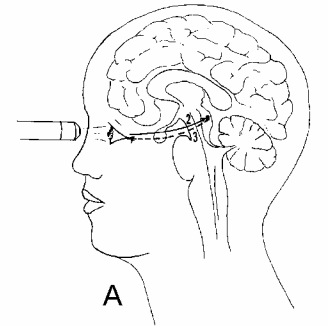
**LEFT rapidly expanding cortical mass = LEFT uncal herniation = dilated pupil LEFT eye. Also, the LEFT cerebral peduncle is compressed = damage to the LEFT corticospinal fibers = RIGHT hemiplegia etc.**

## Brain Death

Modern medicine allows us to maintain vital functions without a conscious brain. In some cases the brain is damaged so that functional recovery is not possible. The most severe condition is **brain death** and is associated with the lack of any cortical or brain stem function. There is no response to pain or verbal stimulation, all brain stem reflexes are absent (pupillary response, vestibulo-ocular response from caloric stimulation, corneal and gag reflexes), and there are no spontaneous respirations. To test for respiratory drive, the ventilator is disconnected and 100% oxygen is delivered to the distal trachea. This maintains oxygenation but allows CO<sub>2</sub> accumulation, which should trigger respiration if there is any central respiratory drive from around the solitary nucleus to an intact lower motor neuron system for respiration. Besides absence of these functions, brain death can only be declared if the patient is not hypothermic or on any medications which could depress brain stem reflexes (curare, high dose barbiturates or other anesthetic compounds).

Brain death is a clinical diagnosis and sometimes it is helpful to confirm it with laboratory tests. One confirmational test is electrocerebral silence as defined by EEG. A problem with this test is the interpretation of a record with artifacts that may mimic brain activity. Another test is to demonstrate the absence of cerebral blood flow as measured by radionucleotide blood flow scanning or the lack of cerebral metabolism as measured by PET (positron emission tomography) or SPECT (single photon emission computerized tomography) scanning. Brain death allows for the procurement of organs for transplantation so strict criteria are required.

- A. Pupillary reflexes are tested by shining a bright light alternatively in each eye, while looking for a **DIRECT** and **CONSESUAL** response of the pupil. In **Brain Death** neither pupil will react to light and the pupils will be in midposition. Tests integrity of CN II and optic tract and CN III = oculomotor nerve and nucleus.
- B. The corneal reflex is tested by touching each cornea with a cotton swab while looking for bilateral contraction of the orbicularis oculi. In **Brain Death** this reflex is absent bilaterally. Tests the integrity of CN V (chief sensory V) and CN VII (motor VII and nerve supplying the orbicularis oculi muscles).
- C. The vestibulo-ocular (or oculovestibular) reflex is tested by irrigating the ear canal with ice water with the head at a 30° angle up from the horizontal, while looking for eye movements. In **Brain Death** there will be **NO** movements of the eyes upon caloric stimulation. Tests the integrity of CNs III, VI and VIII and the VOR circuitry.
- D. The pharyngeal reflexes are tested by stimulating the pharynx and esophagus by passage of a suction catheter into the back of the throat and down the nasogastric tube. Tests the integrity of CNs IX and X.



## Persistent Vegetative State

Persistent vegetative state is the complete unawareness of self and environment with the persistence of some vegetative functions that involve the hypothalamus and brain stem. Patients may have signs of wakefulness and sleep; however, they cannot make meaningful behavioral responses other than to nociceptive stimuli. To be considered as a persistent state, the patient must meet criteria for at least one month. Although these patients are not comatose, they lack awareness of self and from this standpoint can be considered to be unconscious.

The causes of persistent vegetative state include acute traumatic and non-traumatic injury, degenerative and metabolic disorders, and severe developmental malformations. A common cause of non-traumatic acute injury is the hypoxia. The most famous case of hypoxic encephalopathy and persistent vegetative state is Karen Ann Quinlan. Her parents obtained legal permission to discontinue ventilatory support, but after discontinuation she survived in a persistent vegetative state for the next nine years. The most common damage in persistent vegetative state involves the cortex with relative preservation of the hypothalamus and brain stem.

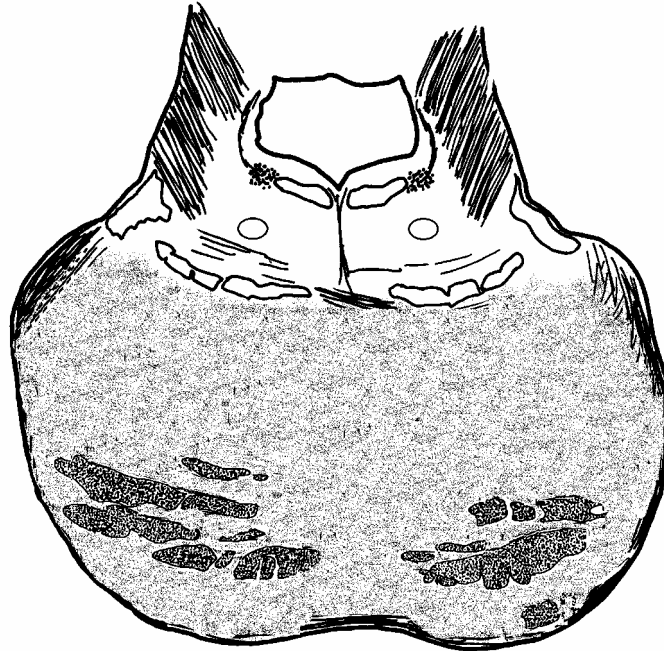
The persistent vegetative state is an unfortunate condition that can drain resources for the care of an individual who is unlikely to make a meaningful recovery. We now realize that this condition does not dictate heroic efforts to maintain survival. Society is providing alternatives in allowing us to determine our fate if we should develop irreversible brain damage in the form of a living will.

	Coma	Brain Death	Persistent Vegetative State	Locked-in Syndrome
Wakefulness	-	-	+	+
Attention	-	-	-	+
Memory	-	-	-	+
Cognition	-	-	-	+
EEG	Abnormal: wide range of abnormalities	Electrocerebral Silence	Abnormal, slow	Normal
Respiration	Variable, may be depressed	Absent	Normal	Usually normal
Sleep Wake Cycle	-	-	+	+

**Problem Solving**

1. The most common cause of **coma** is:
  - A. metabolic dysfunction (drugs or endogenous)
  - B. supratentorial lesions
  - C. pontine hemorrhages
  - D. medullary hemorrhage
  - E. spinal cord tumors
  
2. Which of the following occurs in **locked in syndrome**?
  - A. patient appears alert but has no meaningful cognitive responses
  - B. patient exhibits normal EEG
  - C. patient is unconscious
  - D. patient exhibits no brain stem reflexes
  - E. patient does not respond to pain
  
3. Which of the following occurs in **coma**?
  - A. patient appears alert but has no meaningful cognitive responses
  - B. patient exhibits normal EEG
  - C. patient is unconscious
  - D. patient exhibits no brain stem reflexes
  - E. patient has a flat EEG
  
4. Which of the following occurs in **brain death**?
  - A. patient appears alert but has no meaningful cognitive responses
  - B. patient exhibits normal EEG
  - C. patient has normal respiration
  - D. patient exhibits no brain stem reflexes
  - E. patient responds to pain
  
5. Which of the following occurs in **persistent vegetative state**?
  - A. patient appears alert but has no meaningful cognitive responses
  - B. patient exhibits normal EEG
  - C. patient has abnormal respiration
  - D. patient exhibits no brain stem reflexes
  - E. patient has abnormal sleep-wake cycles

6. Which of the following statements is **FALSE**?
- A. without input from the thalamus, consciousness is not maintained
  - B. the final seat of consciousness lies in the cortex
  - C. cells in the locus coeruleus produce norepinephrine and project diffusely and widely to cortex
  - D. cells in the raphe nuclei produce serotonin and project diffusely and widely to cortex
  - E. the ARAS does not play a role in the sleep-wake cycle
7. Which of the following statements is **FALSE**?
- A. coma follows central herniation involving the diencephalon
  - B. there can be pupillary and eye movement problems following central herniation
  - C. a lesion of the spinal cord does not result in coma
  - D. “locked in” syndrome results from bilateral damage to descending corticospinal and corticobulbar pathways within the basilar (ventral) pons
  - E. the ARAS is involved in the “locked in” syndrome
8. Which of the following statements is **FALSE** regarding the clinical deficits that **can** result from a cortical mass in the **LEFT** uncal herniation?
- A. right hemiplegia
  - B. dilated pupil in the left eye
  - C. left hemiplegia
  - D. it would be possible to have quadriplegia
  - E. damage to the midbrain would never lead to coma
9. Which of the following statements is **FALSE** about **brain death**?
- A. absence of gag reflex
  - B. wide range of abnormalities in EEG
  - C. absence of respiration
  - D. no sleep wake cycle
  - E. absence of vestibulo-ocular reflex upon caloric stimulation



10. Which of the following statements is **TRUE** about the lesion shown here?
- A. the patient is in a coma
  - B. the patient can speak
  - C. the patient can move
  - D. the patient is in a persistent vegetative state
  - E. the patient has normal sleep and wake patterns because there is no damage to the ARAS.
11. Which of the following statements is **FALSE** about the **persistent vegetative state**?
- A. patient can sometimes appear wakeful
  - B. respiration is normal
  - C. patient exhibits sleep/wake cycles
  - D. flat EEG
  - E. none of the above are **FALSE**
12. Which of the following statements is **FALSE** regarding **locked-in syndrome**?
- A. normal respiration
  - B. normal sleep/wake cycles
  - C. normal EEG
  - D. spasticity
  - E. tongue deviates to the right upon protrusion

13. Fill in the blanks in the table below.

	<b>Coma</b>	<b>Brain Death</b>	<b>Persistent Vegetative State</b>	<b>Locked-in Syndrome</b>
Wakefulness	-	-	+	+
Attention	-	-	-	+
Memory	-	-	-	+
Cognition	-	-	-	+
EEG	Abnormal: wide range of abnormalities		Abnormal, slow	
Respiration	Variable, may be depressed	Absent		Usually normal
Sleep Wake Cycle		-	+	+

14. Which of the following statements is **TRUE**?

- A. the arms are flexed in decerebrate rigidity
- B. the legs are flexed in both decerebrate and decorticate rigidity
- C. the lesion lies rostral to the red nucleus in decerebrate rigidity
- D. the lesion lies between the superior and inferior colliculi in decorticate rigidity
- E. none of the above is **TRUE**

15. In brain death:

- A. the gag reflex is normal
- B. the corneal reflex is normal
- C. the pupillary light reflex is normal
- D. the VOR is normal
- E. none of the above is **TRUE**

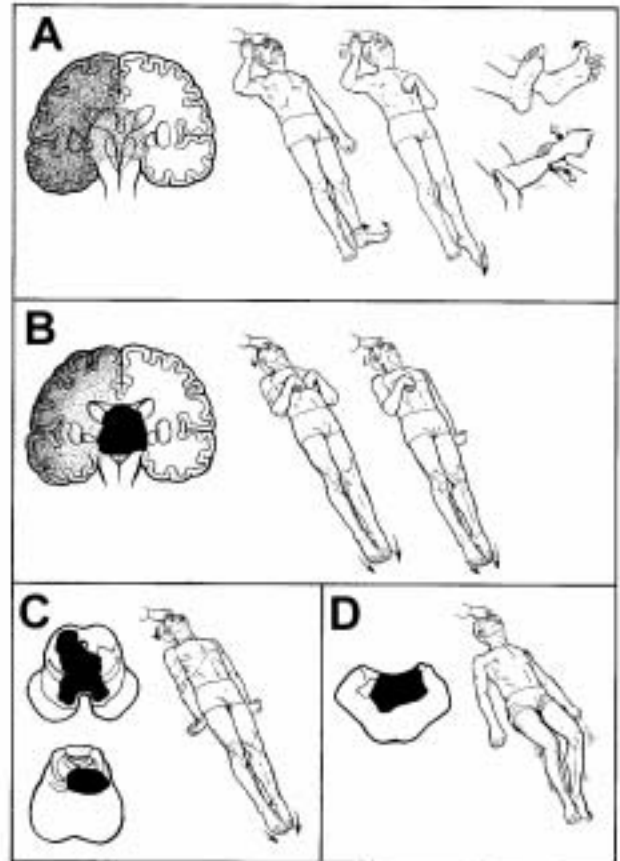
16. Which of the following is **TRUE** regarding Kernohan's notch?

- A. Babinski would occur contralateral to it
- B. lies ipsilateral to the dilated pupil
- C. seen in uncal herniations
- D. is a notch in the internal capsule
- E. two of the above are **TRUE**



17. Which of the following associations is/are **correct** regarding the four different stages of damage shown here?

- A. in **A** there are normal caloric
- B. in **B** there is decerebrate rigidity
- C. in **C** the pupils are meiotic
- D. in **D** pupils are dilated
- E. in **A** the pupils are constricted



18. Which of the following associations is/are **correct** regarding the four different stages of damage shown above?

- A. in **A, B, C,** and **D** there is coma
- B. in **B** there is decorticate rigidity
- C. in **C** caloric stimulation of the right horizontal SS canal with warm water results in movement of the right eye to the left
- D. in **D** pupils are reactive to light
- E. two of the above are **TRUE**

**PROBLEM SOLVING ANSWERS**

- |      |       |               |                 |
|------|-------|---------------|-----------------|
| 1. A | 6. E  | 11. D         | 16. E (A and C) |
| 2. B | 7. C  | 12. E         | 17. A           |
| 3. C | 8. E  | 13. see chart | 18. E (A and B) |
| 4. D | 9. B  | 14. E         |                 |
| 5. A | 10. E | 15. E         |                 |